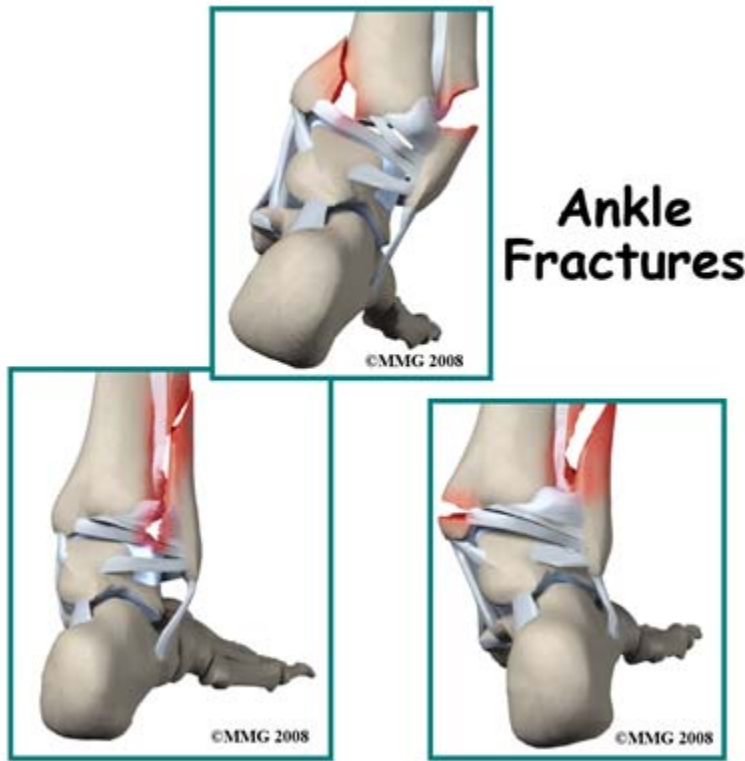


Introduction



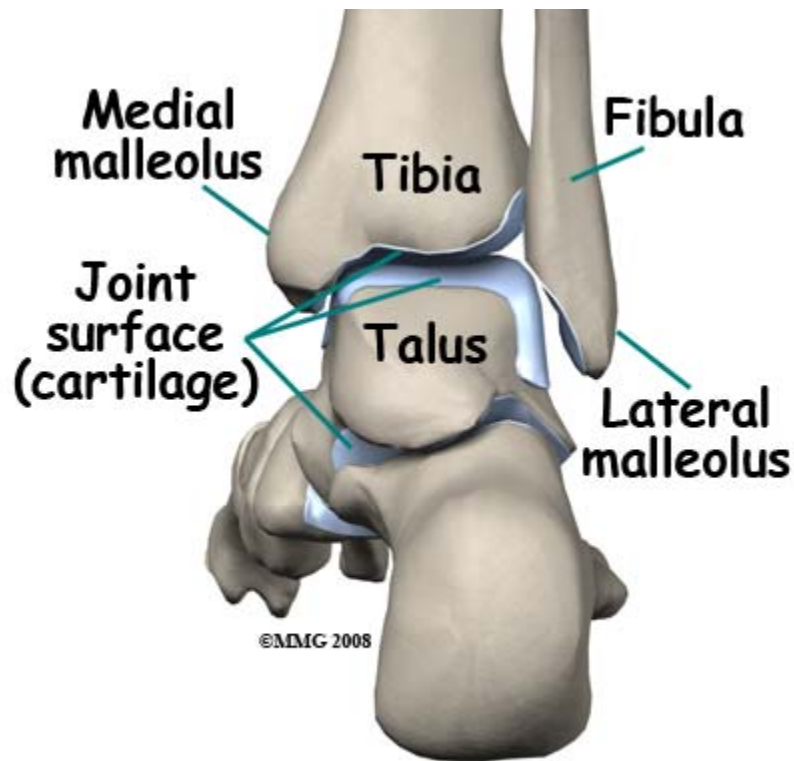
The ankle is the joint between the lower leg and the foot. The weight of the body goes through this joint when we walk and more than one body-weight when we run or jump.

In addition the ankle serves to control *gait* (how you walk) and to balance us while we stand. It is an important joint and vulnerable to injury. When one of the bones that make up the [ankle joint](#) is broken, treatment focuses on restoration of normal joint anatomy and rapid recovery of function.

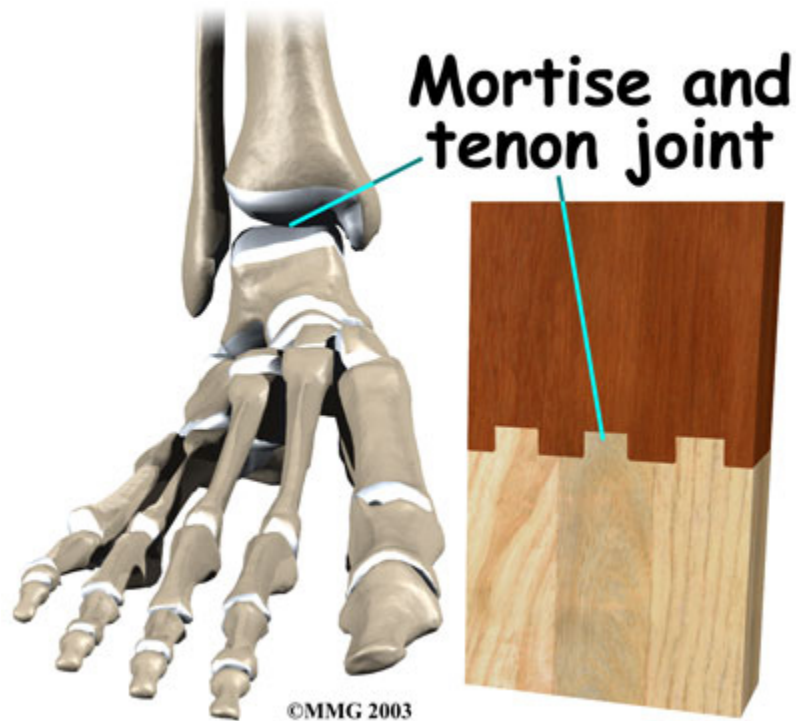
This guide will help you understand:

- what parts of the ankle are involved
- what the symptoms are
- what can cause these fractures
- how doctors diagnose these fractures
- what the treatment options are

What structures are most commonly injured?

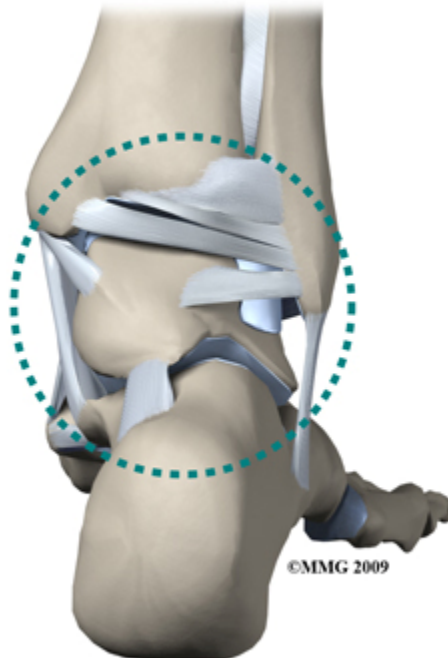


Three bones take part in the [ankle joint](#): the *tibia*, *fibula* and the *talus*. The tibia and fibula are the bones that extend from the knee to the ankle, making up the shin; the talus is the foot bone that forms a joint with the tibia and fibula. Together these form a *mortise and tenon joint*, similar to that used in carpentry. The ankle allows up and down movement but very little rotation, tilt, or side to side movement. In effect the talus is locked into the ankle mortise.



The ligaments of the ankle joint are also important in the understanding of ankle fractures. There are ligaments that connect the fibula and tibia, the tibia and the talus and the talus and the fibula. Together the bones and ligaments form a ring.

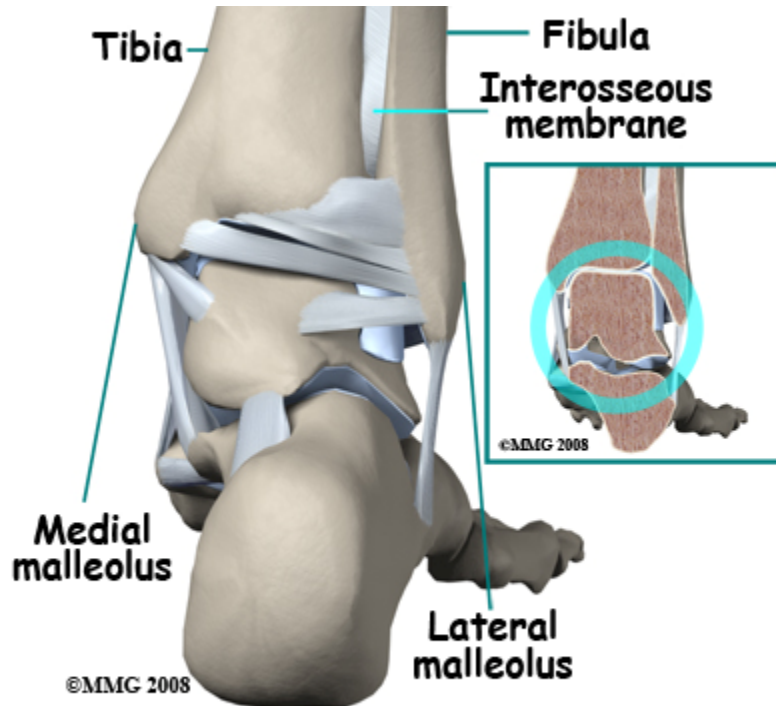
Ankle Joint Stability



The ring of the ankle mortise

A ring usually breaks in two separate regions and this is often the case in the ankle joint. If there is a break in the tibia on the inner side, one has to look for a disruption somewhere between the fibula and the talus on the outer side. This may be a torn ligament which will not show on x-ray but is important none the less. The *interosseous membrane* between the tibia and the fibula must be considered an ankle ligament in this context. It is often torn in ankle injuries.

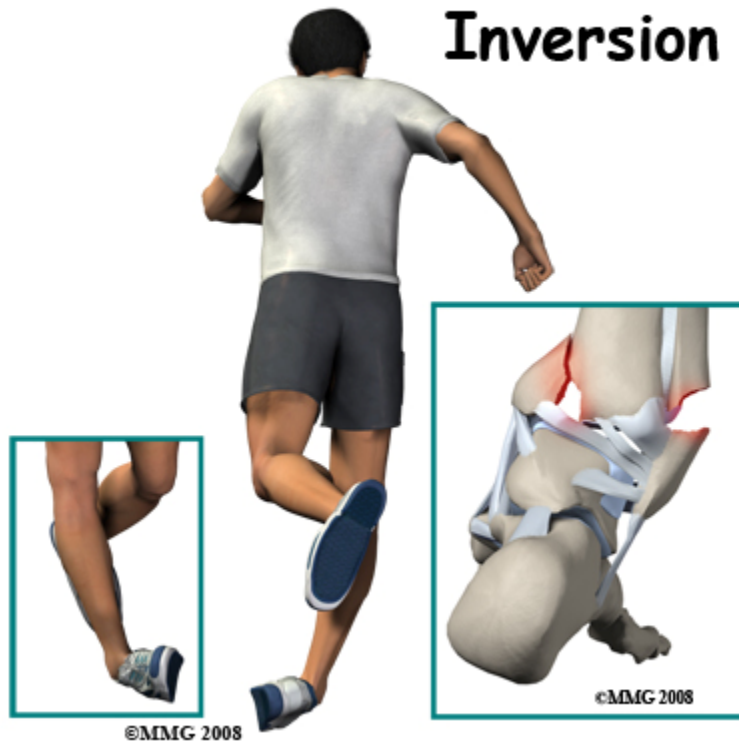If you feel your ankle you will notice that there are hard bumps of bone on the inner and outer sides of the ankle. These are called the *medial* and *lateral* malleoli. They are the lower ends of the tibia and fibula respectively. One, or both of these bony prominences may be injured in an ankle fracture. The shaft of the fibula may also be involved.



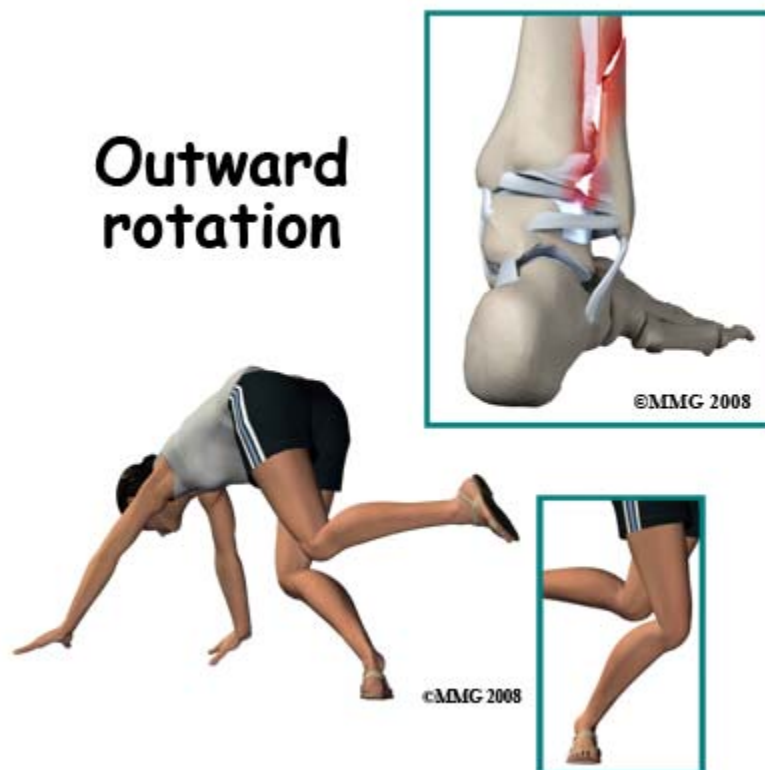
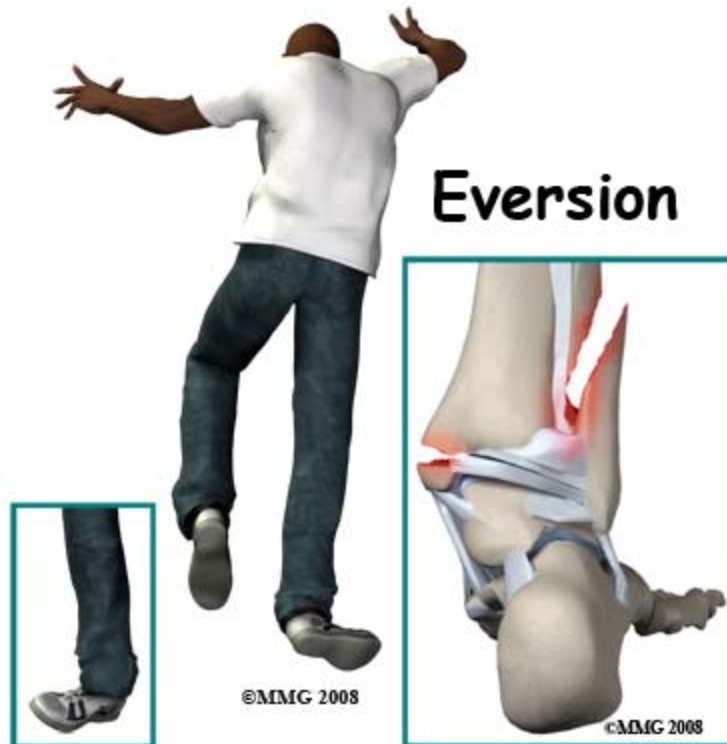You may hear the term *trimalleolar* fracture being used to describe an ankle fracture. The third *malleolus* is the back of the tibial joint surface which can be broken in some patterns of ankle fracture. Although fractures of the malleoli enter the joint they do so outside the main weight-bearing part of the joint so it is less common for the joint surface to be badly damaged in this pattern of fracture.

In the *Pilon* fracture, the most severe form of ankle fracture, the joint surface of the tibia (called the *tibial plafond*) is broken and the weight bearing part of the joint surface may then be crushed or fragmented.

How do fractures of the ankle commonly happen?



Because the talus is locked in the ankle mortise the most common way an ankle gets broken is a severe twist. A common example would be skiing. Ankle fractures were common skiing injuries years ago. With older bindings the foot was trapped in the ski and the bending or rotating forces in a fall were transmitted to the ankle. With modern well-adjusted safety bindings the ski should release when the forces are too great but ankle fractures were common skiing injuries a few years ago.



The fractures occur when the weight of the body is on the affected side, the foot goes one way and the body goes another. Up and down movements at the ankle joint can be

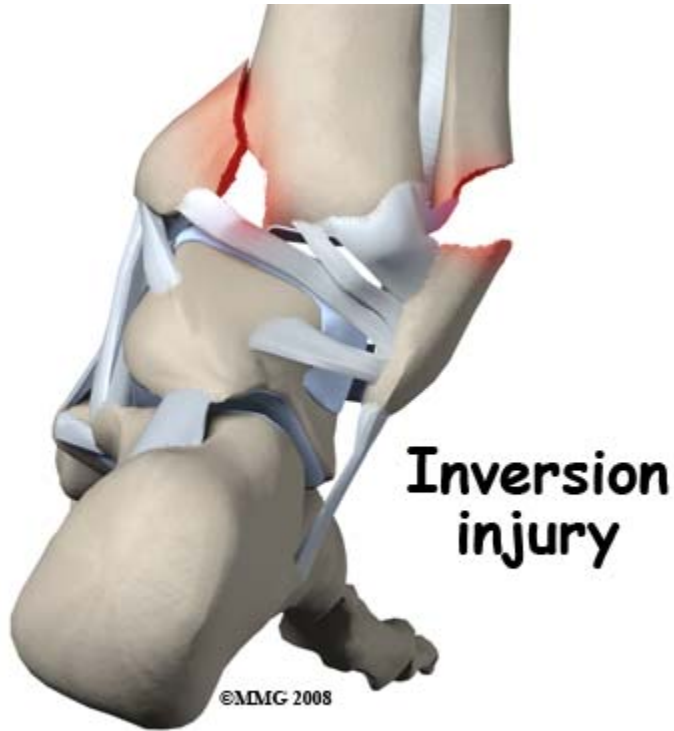compensated for but sideways or rotational forces cannot. This will cause a fracture if they are forceful enough.

There are several different mechanisms that may cause injury and many different combinations:

Inversion

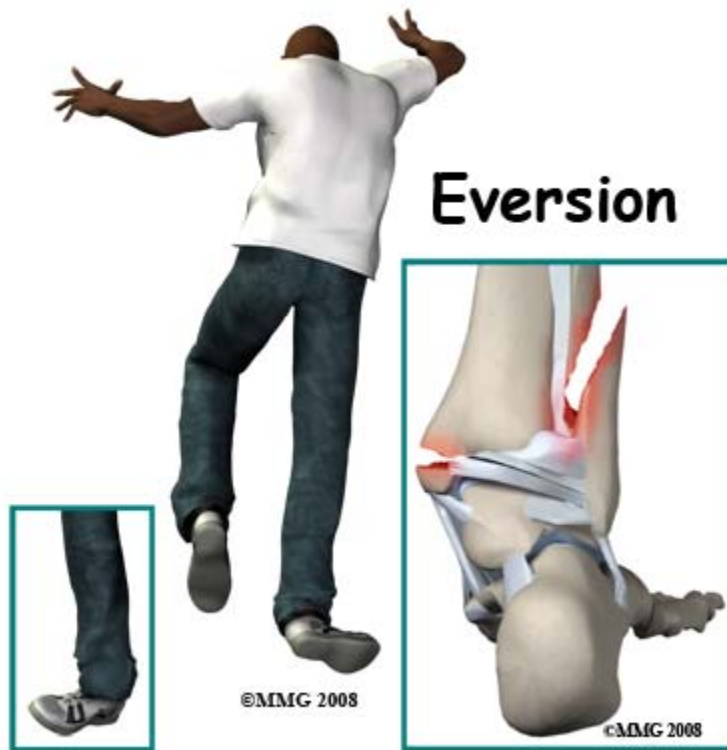

The ankle is turned over so that the outer side almost touches the ground. This is common in sports when cutting or changing direction. Another time this may happen is if your right foot is trapped and your body weight goes to the left. If the bone isn't broken then the ligaments may be stretched or torn and this is an [ankle sprain](#). If the bone does break there may be a pull-off fracture of the end of the fibula, an oblique fracture of the medial malleolus, or both.

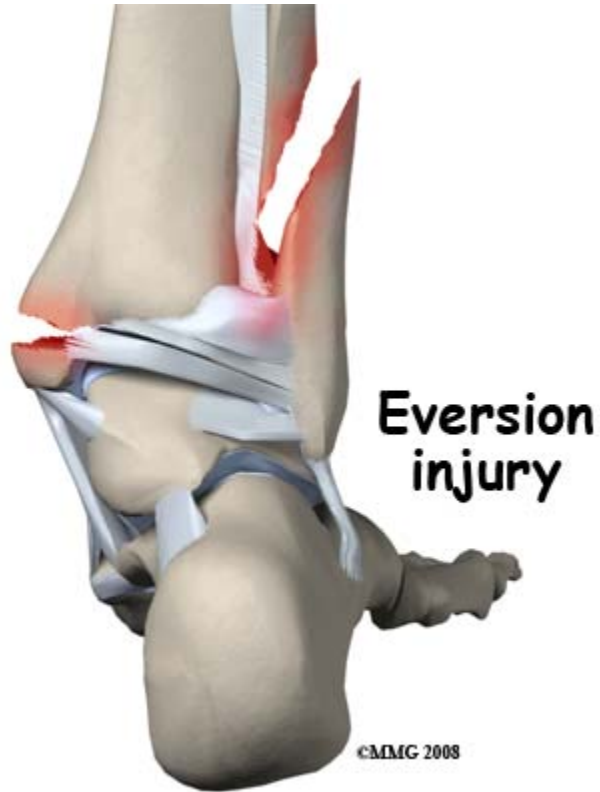

Related Document: [A Patient's Guide to Ankle Sprain and Instability](#)

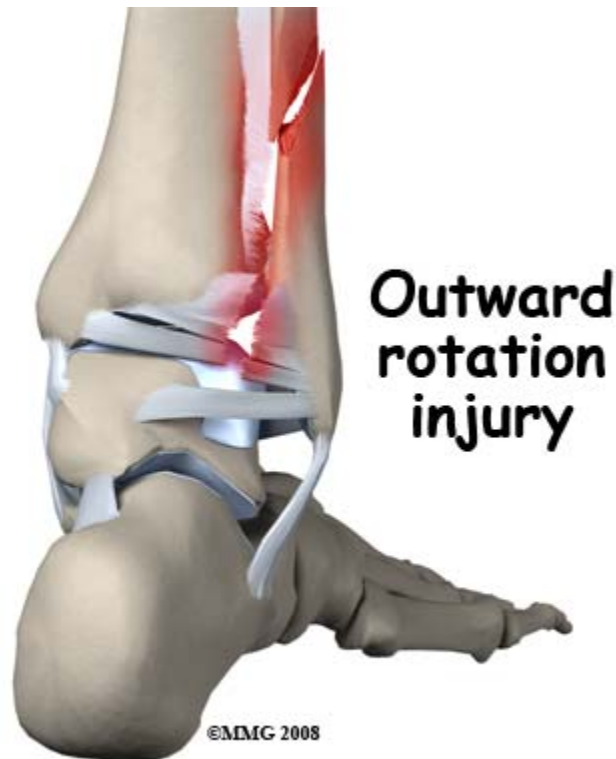Eversion



The foot may be planted or pushed sideways so that the inner side of the ankle is near the ground. This may happen on a slippery surface or if the right foot is trapped and the body weight goes to the right. There will be a rupture of the ligaments on the inner side of the ankle or a pull-off fracture of the medial malleolus. On the outer side there will be an *oblique* (bending) fracture of the fibula with injury to the ligaments that go between the tibia and fibula.



Outward rotation



This occurs when the right foot is planted or trapped and the body weight rotates inwards to the left. The talus rotates outwards relative to the two other bones and springs them apart. There may be a pull-off fracture on the medial side. However, the hallmark of this mechanism of injury is a spiral fracture of the fibula and/or a tear of the ligaments between the tibia and fibula.

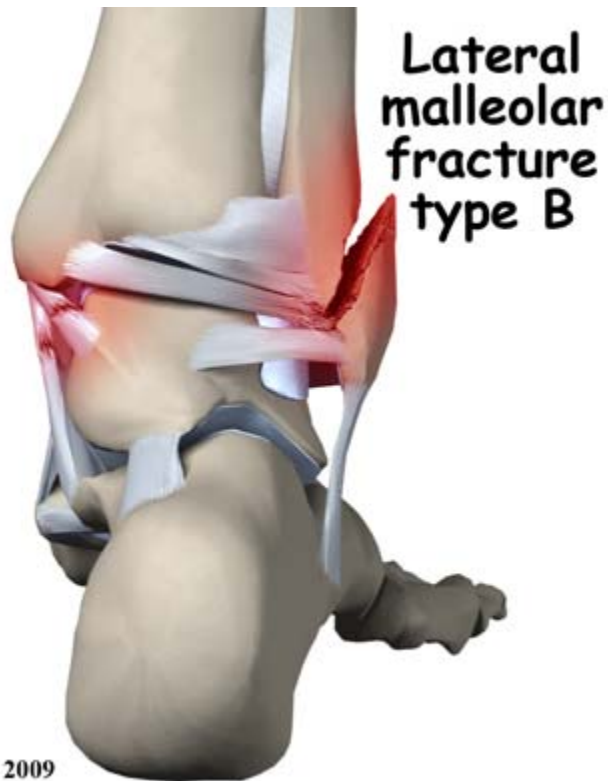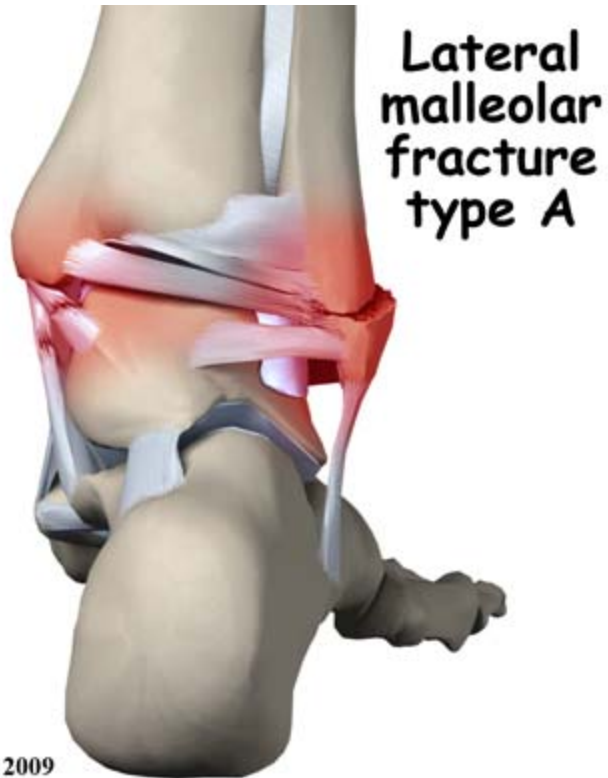When the ligaments between the tibia and fibula are torn the injury is called *diastasis*. This injury may be difficult to detect if there is no other bony injury. The X-ray may show a widening of the gap between tibia and fibula, but it may be difficult to see. A spiral fracture of the fibula is always accompanied by diastasis.

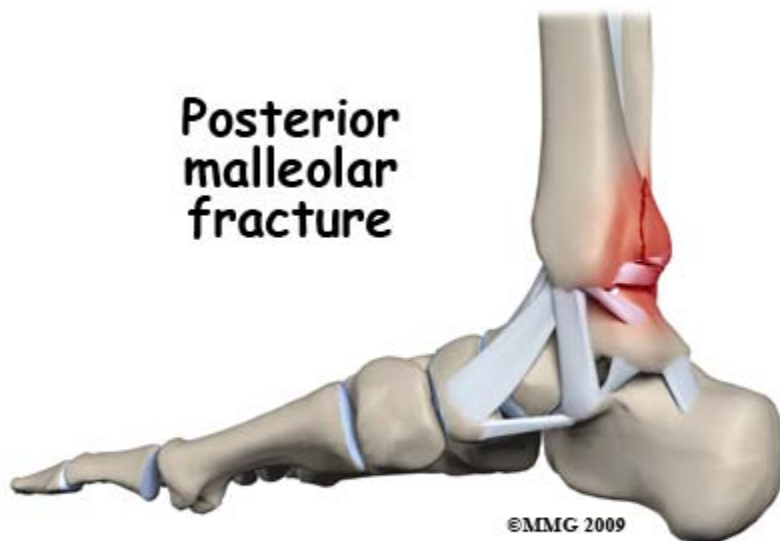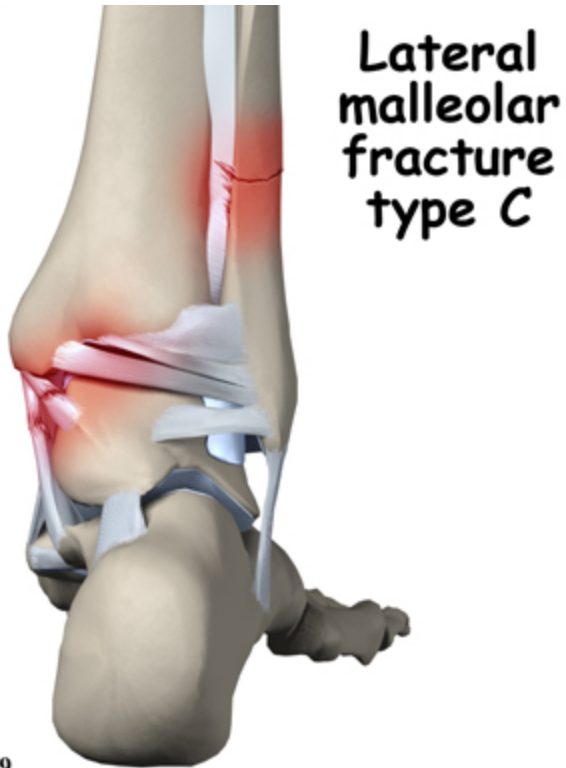
Outward rotation



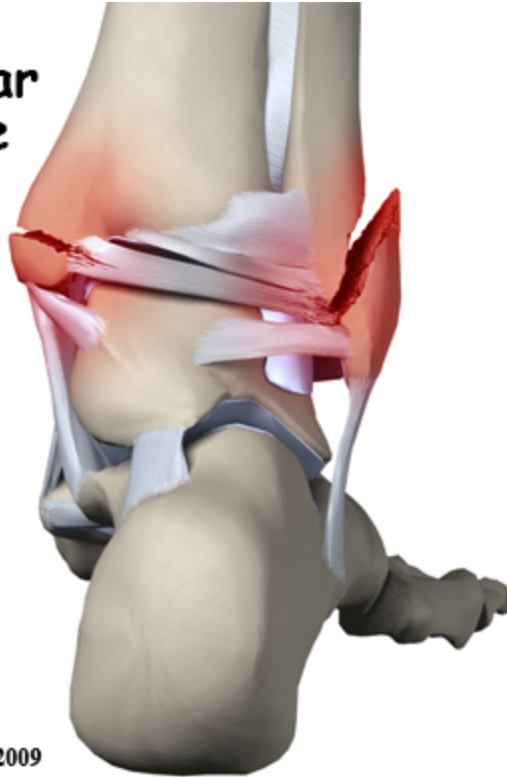Inward rotation

This is less common as a mechanism of injury. The foot can be trapped and the weight of the upper body rotate outwards. The rotation of the talus in the ankle mortise again causes tearing of the ligaments between the tibial and fibula and may cause a spiral fracture of the fibula.



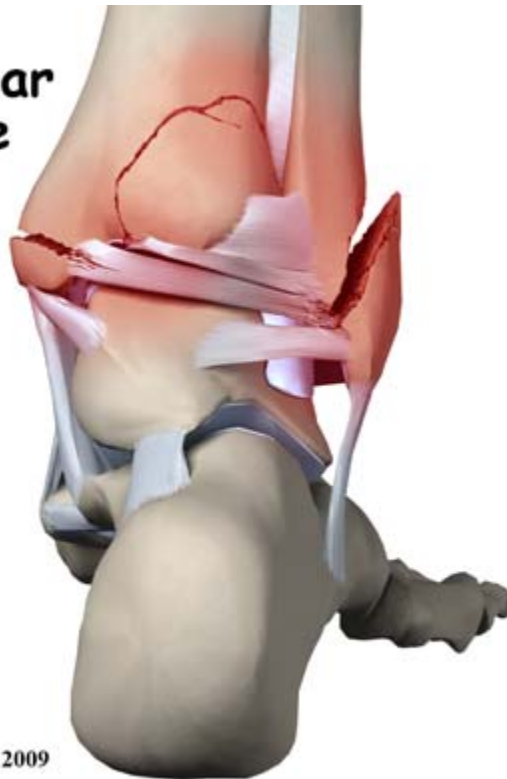

Bimalleolar fracture



©MMG 2009

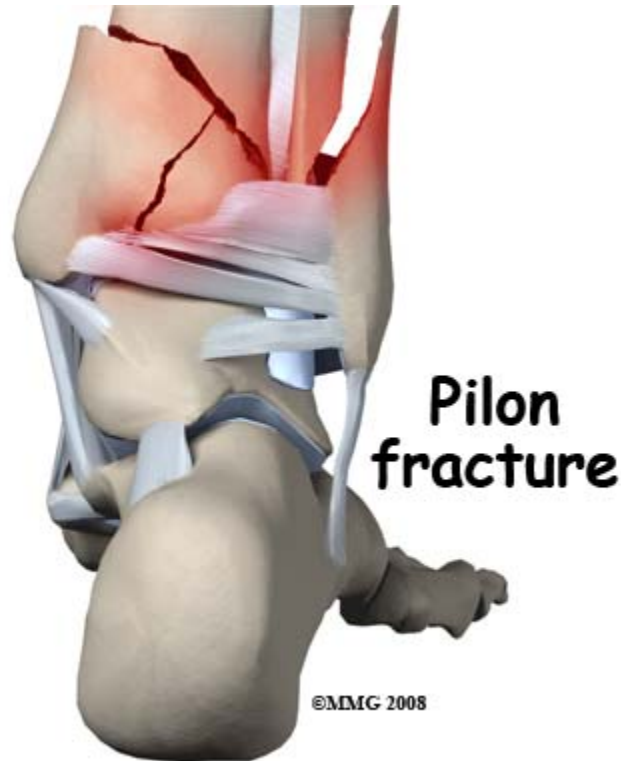
Trimalleolar fracture



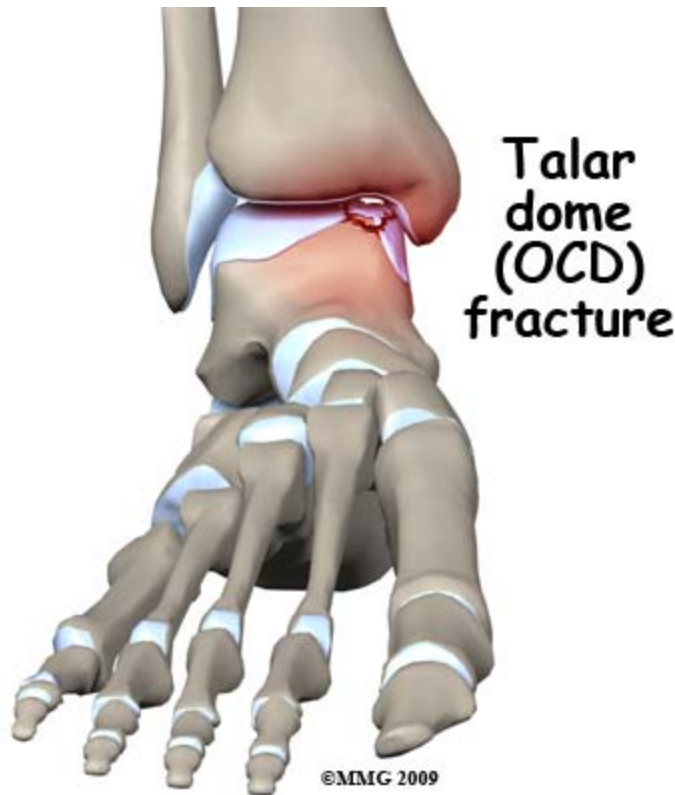
©MMG 2009

Compression

High energy injuries to the ankle may be caused by motor vehicle accidents, falls from a height and some sports. Pure compression is rare; usually it is combined with rotation, inversion or eversion. However, compression results in the fracture to the weight bearing joint surface of the end of the tibia. This *Pilon* fracture is named from the French word for hammer and has the worst outcome of all ankle fractures.



Although some of the most severe ankle fractures occur as a result of MVAs they are more common in two other classes of situation. One would be sports with a higher incidence of sudden changes in direction, landing from a jump, or collisions. The second situation would be slip-and-fall injuries particularly in the elderly. Some ankle fractures are *fragility* fractures and occur in part because the bone is osteoporotic and cannot stand up to normal stresses.



What symptoms do ankle fractures cause?

As with all fractures, immediate pain and loss of function are the most obvious symptoms. The pain is felt in the ankle and is made worse by movements of the leg and foot. Even moving the toes may cause pain in the ankle because the tendons from the muscles that move the toes pass over the [ankle joint](#).

The normal shape of the ankle may be obviously distorted and there is usually swelling and bruising. It's not usually possible (or a good idea) to put weight on a broken ankle. However, in some quite serious injuries it is possible to bear weight with caution and this may mistakenly cause you to think that the injury isn't serious. Open fractures of the ankle are relatively uncommon but if there is a wound it should be investigated immediately. Fracture blisters are common after ankle fractures.

The pain, swelling, and purple discoloration from ankle fractures last several weeks. There is always a significant injury to muscles, tendons, and ligaments (soft tissues) near the ankle and usually a considerable amount of bleeding into the area. Many small blood vessels are disrupted so the circulation is impaired. It takes time for the bones, soft tissues, and blood vessels to heal and the swelling to be reabsorbed. If the ankle is in a [cast](#) or a tight bandage the swelling may cause increased pain.

In the later stages of recovery stiffness of the ankle and foot may be a troublesome symptom. Swollen tissue and collections of blood heal to form scar tissue. The ankle has to be kept immobile for a period of time while the fracture is healing. Then *adhesion* (scar tissue) can bind the bones, tendons, and ligaments together and limit normal movement. It is very common to need an exercise program to recover full range of motion of the ankle after a fracture. Post traumatic [osteoarthritis](#) of the ankle joint occurs relatively rarely but if the joint surface has been damaged there may be persistent aching and pain on bearing weight.

How will my fracture be evaluated?

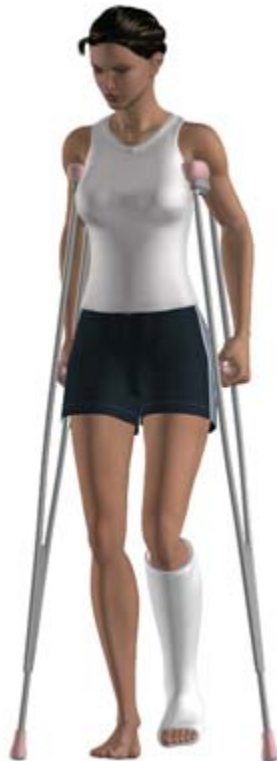First aid for a victim of an ankle fracture consists of keeping the patient warm, splinting the ankle and transporting him/her to hospital. Sometimes it is necessary to straighten the ankle or remove footwear. However in many circumstances the footwear helps the splinting.

In the Emergency Department the first priority will be to assess the victim for other injuries, for shock, and for general medical problems. The splint and footwear will be removed and the whole limb examined for wounds, swelling, tenderness, and deformity. Even though the injury may obviously be on the outer side of the ankle, the inner side will also be carefully examined for tenderness because both sides of the ankle *ring* are often injured. An x-ray of the ankle is taken. In most cases this is enough to make the diagnosis and help prepare the surgical plan. In more complicated fractures, especially the Pilon fracture, a CT scan may be used to make the anatomy of the fracture clearer.

The orthopaedic surgeon's evaluation usually comes after a fracture has been diagnosed. The surgeon will be focused on making sure the anatomy of the fracture is fully understood and then making a plan for treatment. This evaluation takes into account the injury, the patient's health status, their normal level of function, and their expectations for recovery.

What treatments should I consider?

Nonsurgical Treatment



In cases where the fracture is stable and not likely to shift further out of position the injury may be treated in a [cast](#). The maneuver to make the bone fragments return to the normal position is called *closed reduction*. An anesthetic may be needed to reduce the ankle and place the cast.

Once the closed reduction has been performed and the improved position of the fracture fragments confirmed by x-ray, a cast will be applied from toes to just below the knee. If needed the foot will be held over in the position opposite to the direction in which the fracture occurred. The cast may be molded to hold this position. There is usually concern about swelling so the cast is split to allow the limb to swell without causing compression in the tissues.

After a cast has been applied the patient may be mobilized on crutches. It is important to keep the injured foot off the ground and not put any weight on it. When resting, the patient should keep the foot up high to reduce swelling and the throbbing pain that occurs when the leg hangs down.

Movement of the toes is encouraged. This keeps the muscles active, reduces the chance of blood clots in the calf, and helps to prevent adhesion of the tendons.

Follow-up x-rays are usually taken at intervals after the cast has been applied. It is very important to return for follow-up visits and x-rays so that your progress can be assessed.

Casting is usually continued until there are signs of new bone formation on x-ray. Six weeks is the usual cast time for adults. After that the injury may be protected by a walking cast or by a walking splint which can be taken off when the you are not bearing weight.

It usually takes three months for fracture healing to progress enough to allow unprotected weight bearing on the ankle. A period of time to recover strength and mobility may still be needed before the you can return to all normal activities.

It is usually possible to move the fracture fragments back into a good position but there are often some remaining irregularities. The fracture may also shift out of position during the course of cast treatment.

Surgery

The normal ankle is a tight smooth mortise. Irregularities or sloppiness of the [ankle joint](#) may cause [arthritis](#) in the long run. For this reason it is very common to recommend operative treatment for unstable ankle fractures. The main reason this is offered is because orthopaedic surgeons believe that the results of surgery are better than the results of cast treatment in the long term.

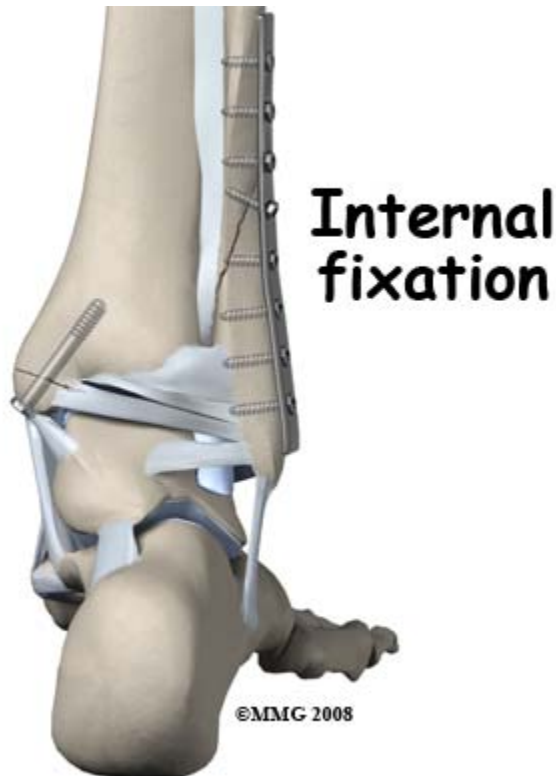After an operation it is not as necessary to immobilize the ankle. Patients are encouraged to move the ankle as early as possible. This reduces adhesions, helps with blood circulation, and reduction of swelling.

Overall patients recover their function more quickly after surgery. Although the details of the surgery are different for every case the fundamental aim of the operation is to put the broken pieces back in exactly the correct position and hold them there with some form of fixation until they heal. Rigid fixation is desirable because then the joint can be moved without disturbing the fracture fragments. You and your orthopaedic surgeon take all these factors into account before a decision for surgery is made.

When surgery is performed, the fibula is usually fixed by a plate fixed with screws. The fracture of the medial malleolus is held with compression screws. It may actually be difficult to see the fracture lines on x-ray after this type of surgery.

Diastasis, the rupture of the ligaments between the tibia and fibula, should be treated with surgery. One or more screws are passed from the fibula to the tibia holding the bones together for six weeks. The patient should remain non-weight bearing while the injured

ligament heals. The screws will fatigue and break eventually so they are normally removed at a second small operation at six weeks.



For Pilon fractures ORIF surgery is also usually recommended (*open reduction* is surgery to manipulate the broken bones into proper alignment and *internal fixation* is the placement of hardware such as screws, plates, or rods). Swelling and blistering often make the situation more complicated. External fixation using a frame has been suggested for the early treatment of these fractures with more definitive surgery later after the swelling has recovered.

After surgical treatment the ankle may be splinted for comfort and protection but in other cases early movement is encouraged. If the fixation is strong the ankle can be gently moved without shifting the fracture fragments. Weight bearing is avoided for six weeks or until there are signs of healing on x-ray. Generally speaking once the fracture has healed, recovery of function proceeds rapidly with the help of an exercise program.

After the bone has healed the metal implants serve no further function. In some situations the plate and screws may be uncomfortable and rub against clothing or boots. In about 20 percent of cases this prompts a small secondary operation to remove the implants.

Rehabilitation

What happens as I recover?

Ankle fractures take six weeks to show some signs of healing on x-ray, and three months to reach 80 percent of their eventual strength. If the fracture is treated nonoperatively it is common for cast and/or brace treatment to continue for three months. Stopping the cast treatment depends on x-ray findings of healing and consolidation of the fracture. The healing process continues for 18 months. Improvements in the strength of the bone, the recovery of normal movement, gait, function, and the gradual reduction of aching and swelling all slowly get better over that period.

In the early stages light exercises to keep the joints moving are all that is needed. Physical therapy is often helpful during the middle and later stages of recovery but is not really needed while the patient is not bearing weight. After that the recovery of normal function is often helped by physical therapy supervision of the progressive exercise program.

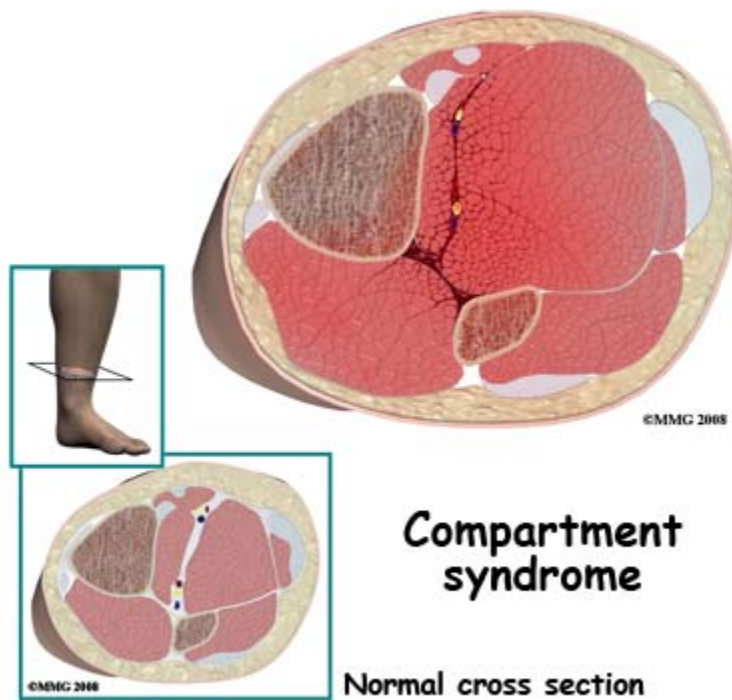
The aim of treatment is to return the patients to their previous level of function - including sports activity. This is usually accomplished in straightforward ankle fractures. Where there is damage to the joint surface or after a Pilon fracture the outlook is less favorable and some stiffness, pain, or loss of function may be a permanent problem.

Complications

What are the potential complications of this fracture?

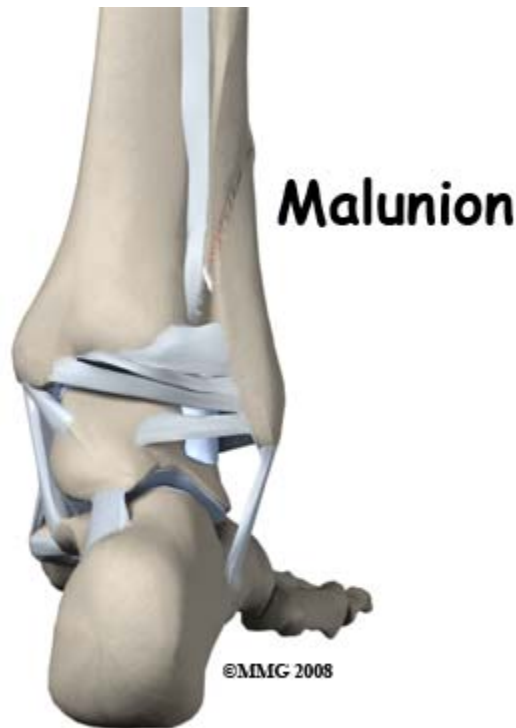In this guide we will discuss the complications that significantly affect the management of ankle fractures. For details of other potential problems please see *A Patient's Guide to Adult Fractures*. We describe complications not because they are common but because the management of your ankle fracture is focused on avoiding them. For example, it may seem strange to be encouraged to move your ankle while it is still sore and swollen; but this helps avoid complications like compartment syndrome or subsequent stiffness.

Compartment Syndrome



When the swelling inside the muscles of the leg reaches a critical point the blood supply to the muscles gets cut off and the muscle tissue dies. This is rare but it can happen with **cast** treatment of ankle fractures especially if the cast gets too tight. The main symptom of this condition is unremitting pain that does not respond to medication. The pain is made worse by moving or stretching the ankle or even the toes. If it is diagnosed quickly and treated urgently by surgery to release the pressure, this problem recovers well. However if parts of the muscle die there will be some long term impairments of the muscle function. The nursing observations to check your foot, wiggle your toes and make sure all is well are done with this complication in mind.

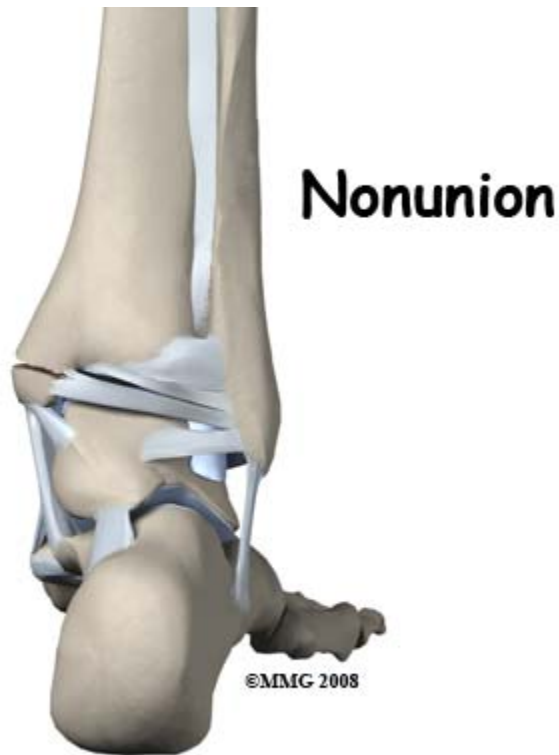Malunion



Healing of the fracture in an incorrect position is quite common when an ankle fracture is treated nonoperatively. The ankle mortise may end up wider than it should be, there may be changes in the rotation of the ankle mortise or irregularities in the joint surface. The significance of these problems depends on the age and expectations of the patient. In a young patient there is concern that malunion would predispose to premature wear of the joint (post traumatic **osteoarthritis**). It is rare for a healed fracture to be operated on to correct malunion; in most cases the likelihood of malunion is identified earlier before the fracture heals.

It is not uncommon for patients who were initially treated in a cast to have surgery when follow up shows that the fragments are going to heal in an incorrect position. The main purpose of close follow up of an ankle fracture is to detect this complication and correct it early.

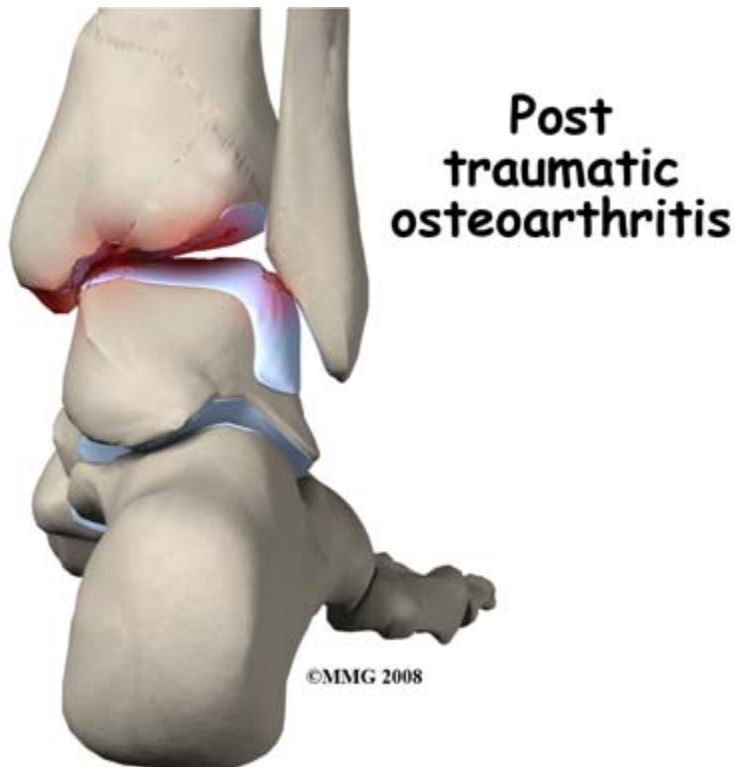Nonunion



Nonunion of a medial malleolus fragment is more common than the fibula. There is often some bony reaction around the nonunion site not just a persistent gap.

Failure of one or other of the ankle fractures to heal is not common. When present it leads to persistent pain and tenderness at the nonunion site. This is normally treated successfully with surgery for open reduction, bone grafting and fixation. The delay in healing may make full recovery of strength and range of motion more difficult.

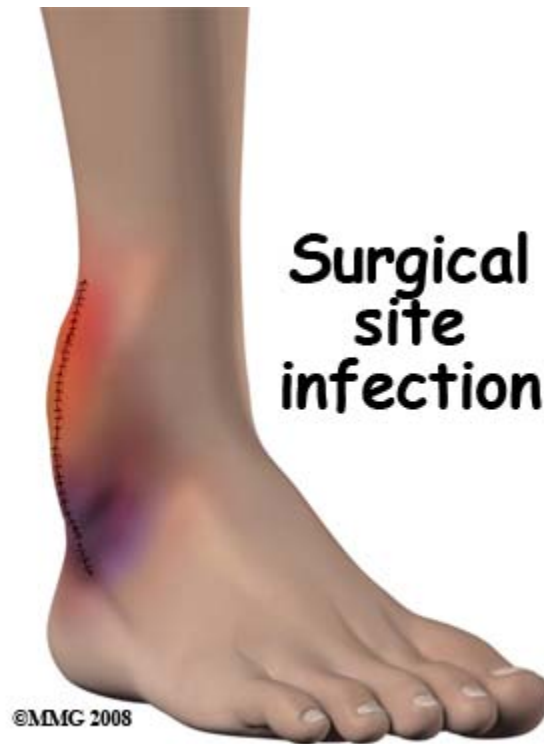Post Traumatic Osteoarthritis



Premature wearing out of the [ankle joint](#) does occur after ankle fracture. In most cases this is because the injury itself caused damage to the joint surface of the talus or tibia or both. After healing of the fracture the patient has persistent aching and stiffness. X-rays show loss of the joint surface and the development of spurs and loose bodies in the joint.

Most people can manage this problem with medication and a small loss of activity. In a small proportion of cases it is severe enough to require surgical treatment. At present the standard treatment is [fusion of the ankle](#) joint to prevent all movement between the talus and the tibia; the possibility of using a [total ankle replacement](#) operation in this situation is being investigated.

Infection



Surgical site infections occur in approximately two percent of operations performed under modern conditions. Because surgery is done for a high proportion of ankle fractures it follows that a few of these procedures will go on to get infected. It is more common with Pilon fractures because of more extensive soft tissue damage and greater exposure of the bones. The wounds remain red, swollen, and tender for longer than normal and may discharge pus. Infection is determined by culturing bacteria from the surgical site.

Treatment for infection will include long courses of antibiotics. It may also include further surgery to drain the wound and redo the fixation. The hardware is usually remains until the fracture heals. It is then removed to help eliminate the infection. With aggressive treatment of infection this situation may heal with no long term problems. However, in a small proportion it is difficult to get rid of the infection.

Hardware Failure

The surgical implants used to hold the fracture fragments in position after surgery are made of metal and subject to metal fatigue. As you know, if you repeatedly bend a piece of wire it will quite quickly break. If you load the metal implants holding your fracture together by putting weight on your injured ankle you run the risk of causing metal fatigue in the plates, screws or wires. It may not hurt to put weight on the ankle right up to the moment when your fixation hardware fails. The the fracture comes apart and you may be back to square one with recovery. If this happens you may need repeat surgery. If the fracture fragments have remained in good position you're ankle may need to be immobilized in a cast. There is a higher risk of malunion and nonunion with hardware failure and a higher risk of surgical site infections with a second operation. When you are asked not to bear weight, it is not a frivolous request.

Summary

Ankle fractures are common injuries which occur across all age ranges and may result from many different activities. With appropriate treatment, surgery in many cases, full recovery of functional activity with a good long-term outlook is achieved.