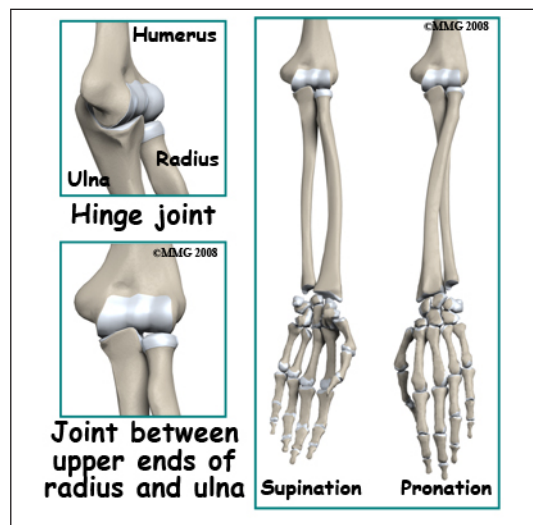


Adult Forearm Fractures

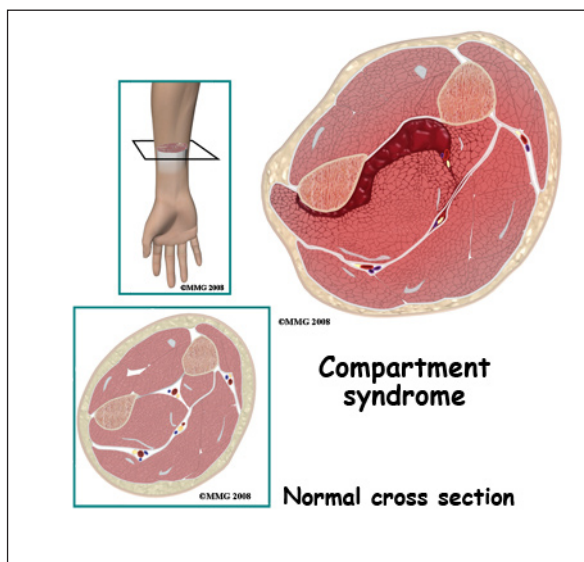
Anatomy

Two bones, the *radius* and the *ulna*, make up the forearm. The ulna is larger than the radius at the elbow and the transfer of force across the elbow joint occurs from the ulna to the distal *humerus* (the upper arm bone). The radius is larger than the ulna at the wrist and force across the wrist joint occurs primarily from the distal radius to the carpal bones of the wrist. The main function of this arrangement is to allow the radius bone to rotate around the ulna in order to place the hand either palm up (called *supination*) or palm down (called *pronation*) - and all points in between. Both the radius and ulna form part of the elbow joint and the wrist joint. Each bone also *articulates* (or moves against) the other at the wrist and elbow joints.



Signs and Symptoms

A fracture of the forearm causes pain and swelling in the forearm. Because the radius and ulna are relatively long tubular bones, when they are broken the forearm tends to look deformed or *angulated*. You will probably not be able to use the arm and the forearm will have a tendency to flop and bend. You may feel the bone fragments shift as you try to use the arm. There is usually bleeding from the fracture into the tissues of the forearm causing significant swelling. The swelling may be extreme leading to one of the possible complications of this fracture, a *compartment syndrome*. A compartment syndrome occurs when the pressure from the swelling disrupts the blood supply to the muscles of one or more "compartments" of the forearm. When this occurs the muscle tissue may actually die if the pressure is not relieved. This results in scarring of the muscles that move the wrist and fingers and they no longer work as they should. This is a serious potential complication.



Evaluation

The primary goal of the clinical evaluation of a forearm fracture is to determine the fracture pattern. There are many variations of forearm fractures including fractures of both the radius and ulna, fractures of either the radius or ulna, and fractures that include a fracture of one or both bones combined with a dislocation at the wrist or elbow joint. The fracture pattern will determine

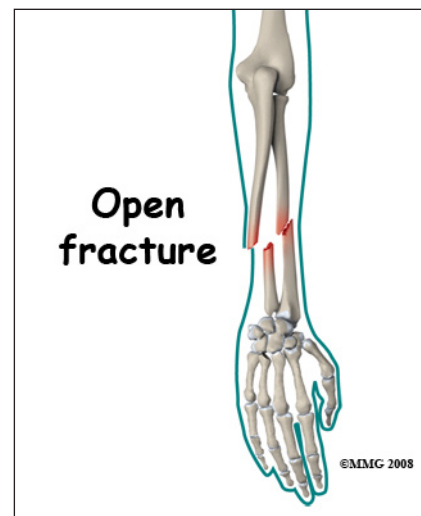
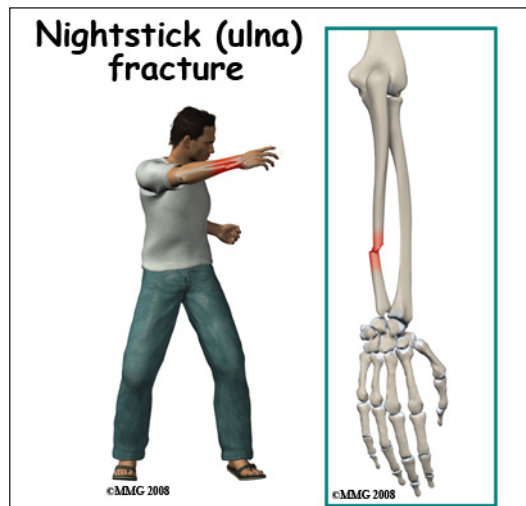
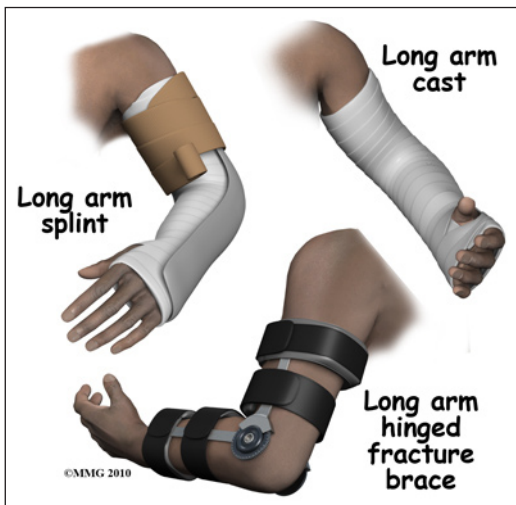how your surgeon proposes fixing the fracture(s). The fracture is evaluated by taking several x-rays of the forearm that include the elbow joint and wrist joint. Special imaging studies such as a CAT Scan or MRI Scan are usually unnecessary. Your provider will also want to make sure that there has been no damage to the nerves and blood vessels and that there is no evidence of a compartment syndrome beginning. This can usually be accomplished with a careful physical examination.

Treatment

Nearly all forearm fractures require surgery. If the fracture is an *open* fracture (also called a "compound" fracture) there is a surgery that will be necessary immediately to reduce the risk of infection. An open fracture occurs when there is a laceration through the skin at the fracture site. This can be caused by either the ends of the fracture tearing out through the skin or an external object puncturing the skin from the outside. If there is evidence that a compartment syndrome is beginning, surgery will be immediately necessary to relieve the pressure in the muscle compartments affected; the fracture will be fixed during the procedure as well.

Nonsurgical

If the fracture is not "open" and there is no concern for a compartment syndrome, you may be placed in a bulky, long arm splint to stabilize the arm until surgery can be scheduled.

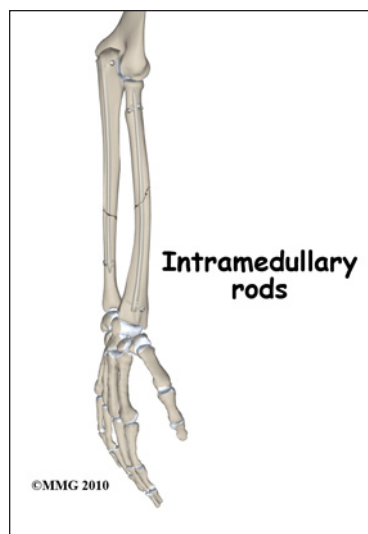
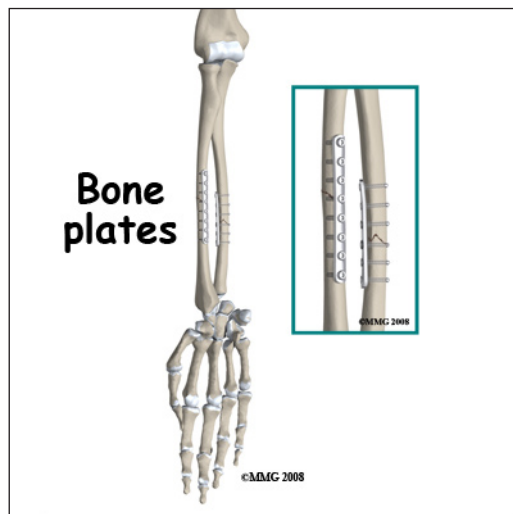


In some cases, surgery may not be necessary. If the fracture involves only the ulna and the fracture fragments have not *displaced* or *angulated* (meaning that they remain aligned with the two ends of the fractured bone together), your surgeon may recommend treating the fracture with a cast or fracture brace instead of surgery.

Surgery

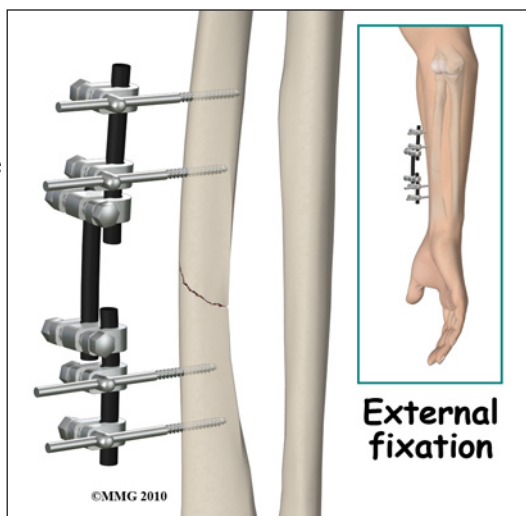
Surgical treatment of forearm fractures can be performed in three ways: a metal plate and screws along the side of the bone, a metal rod inside the bone or an external fixator with metal pins through the skin.

Most forearm fractures require *Open Reduction and Internal Fixation (ORIF)* using a metal plate and screws. This type of treatment allows the fracture to be fixed *anatomically*, meaning that the bones can be restored to their normal position and held there with the plate and screws until healing occurs. It is important that the radius and ulna be restored as close as possible to normal to ensure that the radius can rotate around the ulna. This means that both the angle and the rotation of the two fracture fragments needs to be restored to normal in addition to making sure that the two ends of the bone are back together. This is best achieved with ORIF using a plate and screws in most cases.



The intramedullary rod is not commonly used to treat forearm fractures, but in some special circumstances it can be used to reduce the need for making incisions in the forearm. The intramedullary rod is a metal rod that is placed inside the hollow shaft of a tubular bone such as the radius or ulna. The metal rod can be inserted into the bone through a small incision at either the wrist or elbow. The intramedullary rod is inserted with the aid of a special X-ray machine called a fluoroscope. The fluoroscope allows the surgeon to see an X-ray image of the bones on a television monitor and guide the placement of the intramedullary rod by viewing this image.

External fixation is not commonly used for forearm fractures. This type of treatment may be necessary for open fractures when the risk of infection is high or there has been loss of bone leaving a gap; for example, when the fracture is due to a gunshot. The external fixation device allows the surgeon to place metal pins through the skin and into the bone fragments away from the fracture site. These metal pins are then connected to a metal frame *outside the skin*. Thus, the fracture is stabilized, but there are no foreign materials (such as metal plates) in the fracture site to harbor the infectious bacteria. The fracture is less likely to develop an infection of the bone (called *osteomyelitis*).



Complications

Nearly all fractures can result in damage to nerves and blood vessels and forearm fractures are no exception. Infection may occur but is rare after ORIF. The risk of infection increases if the

fracture is an open fracture. One of the most dreaded complications of a forearm fracture is the compartment syndrome discussed above. Your surgeon will monitor the situation carefully during the first several days and weeks before and after surgery. A special pressure monitoring apparatus can be used to check the pressure in the muscle compartments if there is concern. If your surgeon thinks that a compartment syndrome is occurring, then a surgical procedure to relieve the pressure on the muscles will need to be done immediately.

The fracture fragments may fail to heal; this is referred to as a *nonunion*. The fracture fragments may also heal in an unacceptable alignment; this is called *malunion*. Both of these complications may result in pain, loss of strength and a decreased range of motion of the shoulder. A second operation may be needed to treat the complication.

Rehabilitation

Many surgeons do not use a cast or brace after stable ORIF of forearm fractures. Rehabilitation will begin once your surgeon feels that the fracture is stable enough to begin regaining the range of motion in your wrist and elbow. Your rehabilitation program will be modified to protect the fixation of the fracture fragments. Your surgeon will communicate with your physical therapist to make sure that your rehabilitation program does not risk causing the fixation to fail. If the surgeon feels that the fixation is very solid, you may be able progress your program quickly; if the fixation is not so solid, the speed at which you progress may need to be slowed until more healing occurs. The prognosis for simple forearm fractures is generally excellent. For those more complex forearm fractures that include dislocations of either the elbow or the wrist, there is more risk of loss of range of motion in either the elbow or wrist.

