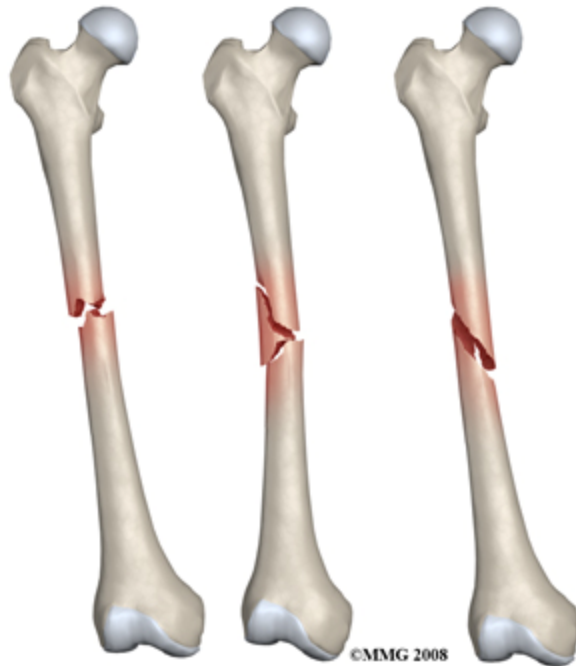


Fractures of the Femur



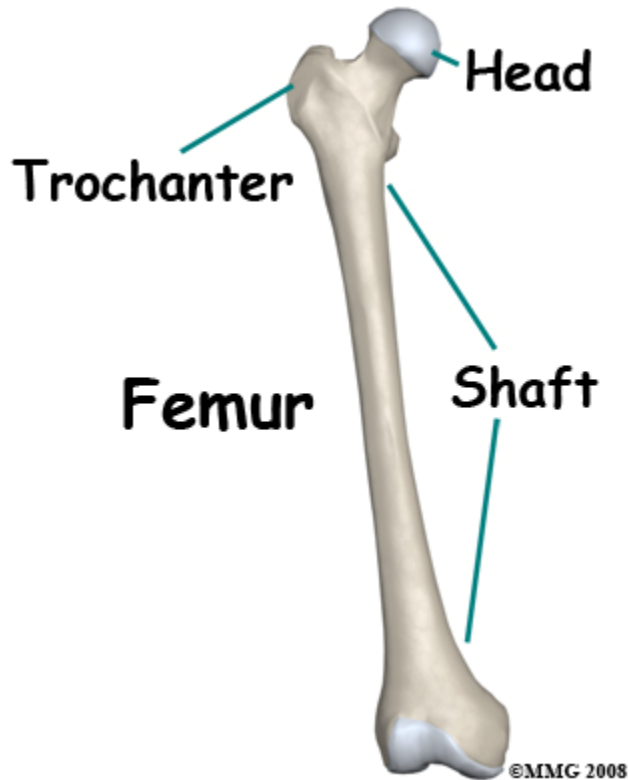
The thigh bone, or *femur* is the longest and strongest bone of the body. It takes a lot of force to break the femur in an adult so it is often accompanied by other injuries. The fracture is a disabling problem, severely limiting mobility until it is stabilized.

Until recently the most common way to treat a fractured femur was to apply traction, the source of a thousand cartoons and jokes. Fortunately, modern treatment usually stabilizes the bone quite early on and allows you to move around on crutches.

This guide will help you understand

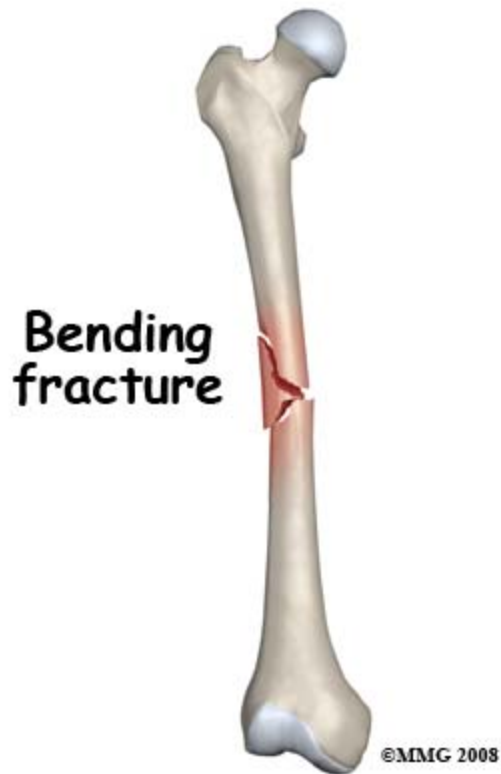
- what parts of the shoulder are involved
- what the symptoms are
- what can cause these fractures
- how doctors diagnose these fractures
- what the treatment options are

What structures are most commonly injured?



The femur extends from the hip to the knee and represents one fourth of the height of the average adult. You can feel the lower end of the femur at the knee. The upper end is deeply buried in the muscle at the hip, but you can feel the bony bump of the greater trochanter on the outer side.

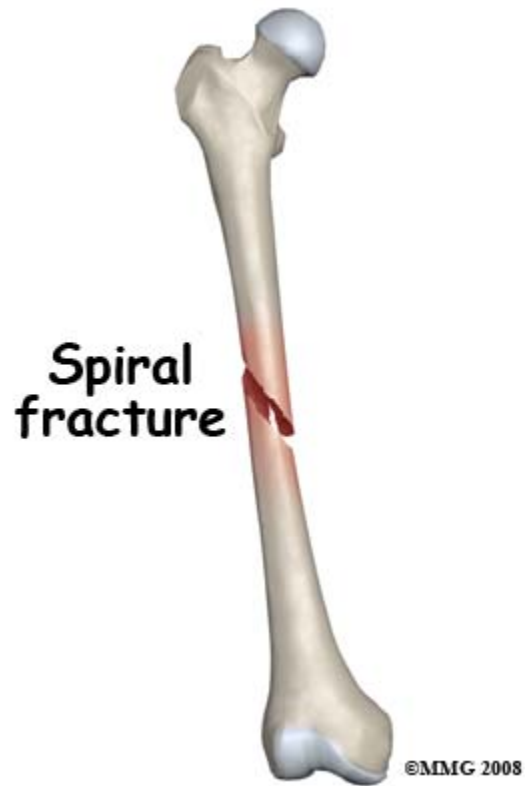
The shaft of the bone is a hollow tube with dense strong compact bone on the outside and fatty tissue with no structural strength inside. The shaft breaks when the bone is stressed by impact, bending, twisting or compression.



The bone injury is only a part of the total picture when a fracture occurs. Injury to the muscles, tendons, ligaments, skin, blood vessels and nerves may be more important than the broken bone. This is particularly true of femur fractures. The force needed to break the thigh bone often causes a lot of damage to the other structures in the thigh. An open fracture in which the bone comes out through the skin is a especially severe problem.

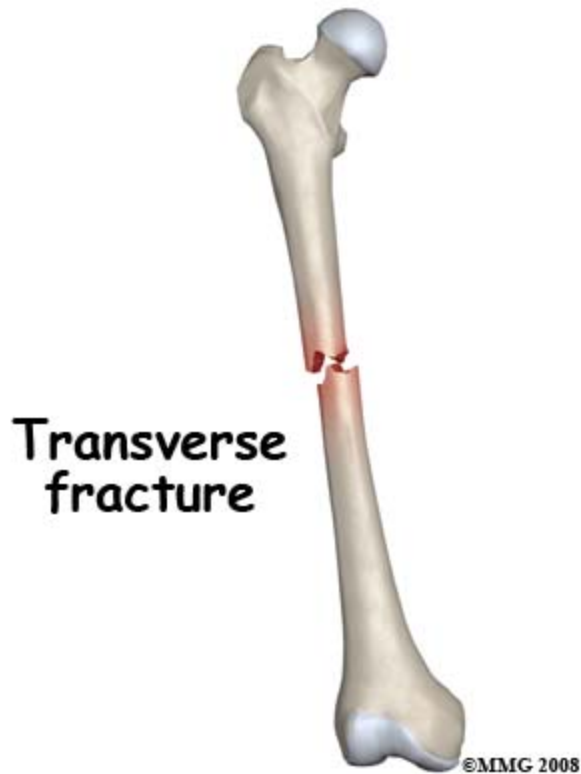
How do fractures of the femur commonly happen?

Femur shaft fractures occur in high energy trauma such as motor vehicle accidents and falls from a height. Gunshot and blast injuries also cause severe open fractures of this area. Lower energy accidents which may cause a fracture of the thigh bone include collisions in sports, skiing injuries and twisting injuries.



Impact against the thigh causes a bending force which compresses one side of the bone and stretches the other. This may result in a short oblique fracture or a three part fracture with a short triangular fragment.

A twisting force can be applied to the thigh bone when the foot or lower leg is trapped and the weight of the upper body is rotating. This causes a spiral fracture of the bone.



Compression along the line of the bone causes a transverse fracture. This may occur in a car accident when the knee strikes the dash and the force is transmitted up the bone.

The bone injury is only a part of the total picture when a fracture occurs. Injury to the muscles, tendons, ligaments, skin, blood vessels and nerves may be more important than the broken bone. This is particularly true of femur fractures. The force needed to break the thigh bone often causes a lot of damage to the other structures in the thigh. An open fracture in which the bone comes out through the skin is a especially severe problem.

What symptoms do femur fractures cause?

The main immediate symptom from the injury is pain in the thigh and inability to use the leg. It is very rare for anyone to be able to walk on a broken thigh bone and it shouldn't be attempted. The leg is often unstable and does not move as one. Usually, the fractured leg will be shorter than the other one and distorted. There will be swelling and tenderness at the site of the fracture. There may be loss of sensation and movement of the foot if the nerve or blood supply has been affected. If the bone has come through the skin the wound will be obvious. Internal bleeding from a broken femur can be significant causing rapid heart rate and low blood pressure (shock).

Pain will continue to be a feature for several weeks as the thigh bone heals. This will be lessened if the bone is stabilized by surgical fixation. Swelling, tenderness and massive bruising are also symptoms that last for weeks.

How will my fracture be evaluated?

First aid evaluation at the scene of the accident will include questions about the nature of the accident, site of pain and ability to move the leg. The shock status of the patient will also be evaluated. The leg will be assessed for wounds, sensation and blood supply. Usually the leg will need to be splinted prior to transport to hospital. The patient should be kept warm and still.

In the Emergency Room the patient will be further assessed for shock and blood loss as this can be significant. The patient will be checked carefully for other injuries especially in the case of a high energy accident with its potential to cause multiple trauma. The vascular and nerve supply of the limb will be carefully checked. The limb will be stabilized with splints, sandbags or skin traction. Careful palpation of the leg, paying attention to the knee and shin as well as the thigh and hip may give an indication of other injuries. Routine tests are done to evaluate blood loss and general body biochemistry prior to an anesthetic.

X-rays of the thigh are a vital part of evaluation of this injury. The standard views are an anteroposterior (AP) view of the whole thigh bone from hip to knee and a lateral view of the shaft. It is extremely important to get satisfactory x-rays of the hip and knee joint to make sure these regions have not been fractured also. Even with good X-rays a small number of [hip fractures](#) are not discovered at the initial evaluation. CT or MRI scanning is not usually needed for these fractures.

What treatments should I consider?

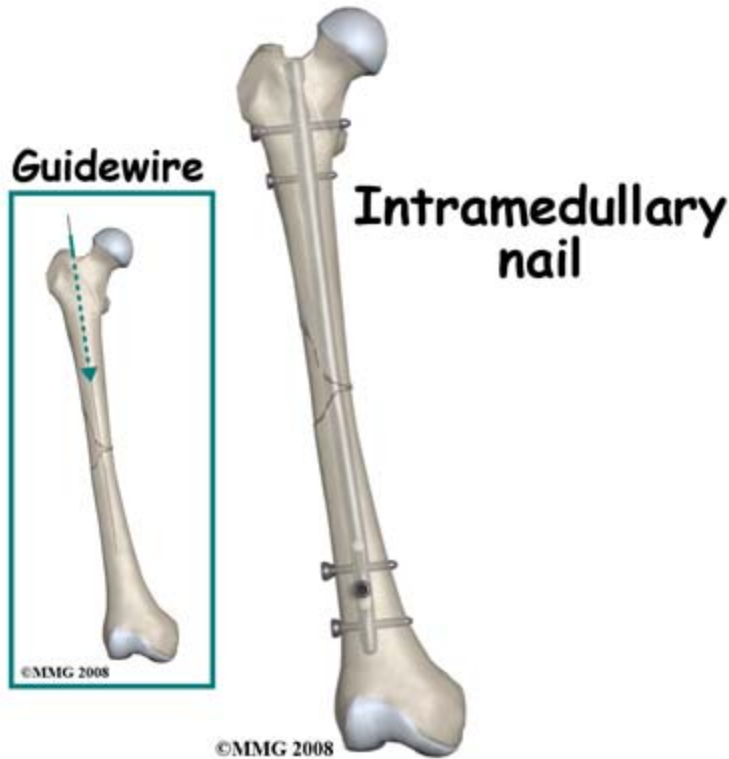
Surgery

A few years ago this type of fracture was most commonly treated in traction. However, in North America the majority of patients with a broken thigh bone are now treated by surgery. This surgery consists of straightening (reducing) the fracture and stabilizing it with a metal rod passed inside the bone and fixed to the bone at the top and bottom to prevent shortening and rotation.

Traction may be recommended in some cases where the risks of a more major operation seem too great. A metal pin is passed through bone either just above or just below the knee. The leg is supported by slings and splints and 15 to 25 lbs weights are attached by cords and pulleys to the pin. The principle of traction is that pulling on the bone both straightens it and keeps it still.

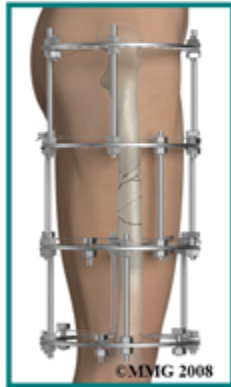The traction must be maintained until the healing process is advanced to the point where the fracture will not move when the traction is taken down. Usually this takes six to eight weeks in an adult. Following this period in traction the fracture must still be protected in a body [cast](#), otherwise it is liable to shorten, angulate or rotate. The body cast, from chest to ankle is maintained for some months until the fracture is united. If the fracture has a very stable pattern it may be possible to treat it in a cast brace after the initial period in traction.

Apart from the significant inconvenience of prolonged bed rest for traction and prolonged immobilization, this way of treating the fracture was found to cause a number of problems such as malunion, nonunion, stiffness, weakness and poor functional recovery from the injury.

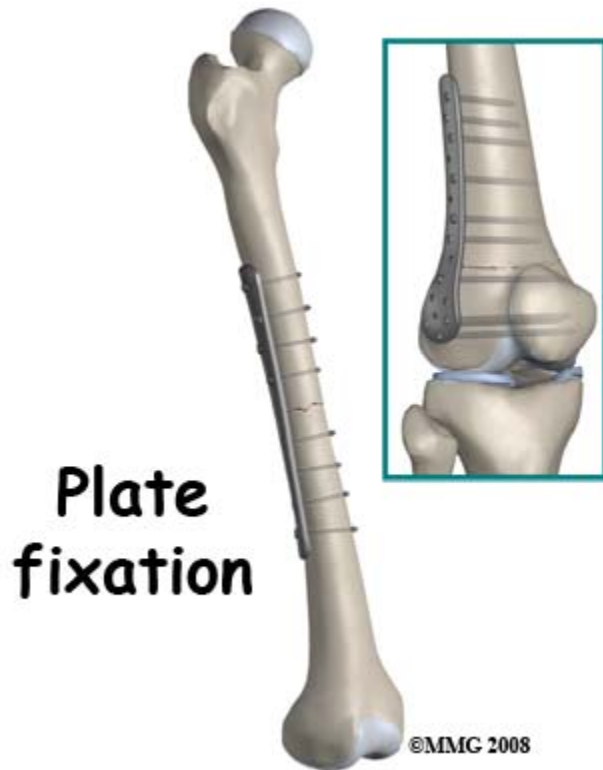


Thus the reason for treating a fractured femur by surgery is because the results of non-operative treatment are not reliably good. Surgery is done under general or spinal anesthetic. The bone is straightened and kept straight by traction. Then a small hole is made at the top of the thigh bone and a thin wire is passed down inside the bone, crossing over the fracture and into the lower fragment. The inside of the bone may be reamed to ensure a snug fit then an Intramedullary Rod (IM Rod or IM Nail) is passed over the guide wire and secured with screws at either end.

External fixation



With some fracture patterns or with open fractures, an external fixation device may be used. To apply an external fixator, the bone is straightened and large threaded pins are passed into the bone fragments above and below the fracture. These pins are attached to a rigid framework outside the thigh which holds the fragments in position while the healing process takes place.



When the fracture extends far down the shaft towards the knee a plate may be used. The greatest advantage of operative treatment of a fractured femur is that it allows the patient freedom to move, to walk on crutches very soon after the surgery and to leave the hospital early. The bone is not healed by the surgery, but it is held still to improve the chances of healing. The quicker recovery of normal movement of the hip and knee prevents future problems with stiffness and weakness.

Implants are often removed after the bone is healed. The external fixators are always removed. Plates are also removed quite frequently as they may give the patient some symptoms and can be felt through the skin. Removal of IM Rods is done when they cause symptoms. The removal operation is relatively simple and recovery is usually quite rapid (six weeks). However, the bone may need some time to regain full strength after the hardware has been removed.

When there are no symptoms attributed to it, removal of the hardware is controversial. Some surgeons advocate it because the presence of a plate or a rod may weaken the bone long term; others leave the hardware in and point to the small but significant incidence of re-fracture in the three months after the implant is taken out.

What happens as I recover?

The normal uncomplicated process of healing takes six weeks to obtain 50 percent of eventual strength, three months to reach 80 percent and may continue with consolidation and remodeling of the fracture for 18 months. The consequences of this timetable are that the fracture needs protection for the first three months. Early on this means using crutches and not putting much weight through the injured leg. Otherwise the fixation will fail.

Orthopaedic surgeons usually monitor the healing of a thigh bone fracture with x-rays at intervals. When new bone formation (callus) is evident bridging across the fracture, the patient may be encouraged to put more weight on the leg. Once the fracture shows x-ray signs of consolidation you can use the leg more normally and return to heavier activities and sports. This stage is usually between three and 18 months post-injury and depends on the recovery of muscle strength and endurance as much as bone recovery. The fact that the healing process may go on for 18 months means that the symptoms of aching, throbbing, swelling and weakness may go on improving for a long time after the bone appears 'healed' on x-ray.

Physical therapy is needed at two stages in the recovery from a thigh bone fracture. In hospital when the patient is getting up on crutches the physiotherapist will assist with mobilization and teaching the patient to move the rest of the leg safely. At a later stage, when the bone is healing and recovery of strength and endurance is important the physical therapist will supervise a program of exercises for range of motion, strength and conditioning.

Overall the prognosis for recovery from a fractured thigh bone is encouraging. Most people heal the bone in good position and recover near normal function. Most of those who do not recover full function have had the injury or its treatment complicated by one or more of the problems discussed in the next section.

What are the potential complications of this fracture?

When the treatment of a fracture encounters a problem the case is described as "complicated". Most of the general complications that can affect a fractured femur are considered in some detail in Patient's Guide to Fractures. Here we focus on the problems that are specifically relevant to fractured thigh bones.

Malunion

When the bone heals with shortening, rotation or angulation it is said to be malunited. Before it heals it could be described as "malaligned" but this may be correctable. Once a bridge of bone has formed across the fracture the position of the fragments is set and will not change without surgery or re-fracture. This complication is very common where traction is the main method of treatment. It can occur with surgical treatment; fixing the fracture with malrotation is particularly common. The result of shortening is a permanent limp with one leg shorter than the other. If the fracture is malrotated the feet don't point in the correct direction and this also affects gait. If the fracture heals with an angle this tends to put uneven stress on the nearby joints and can lead to post-traumatic arthritis in the long term. There is often a combination of malalignments.

Malunion is only treatable by surgery to cut through the bone, re-align it in the correct position, and fix it. This is a major operation and needs careful consideration. In some situations it may be best to accept the problem and leave it alone.

Nonunion

This means that the healing process has failed and bone has not formed in the gap between the fracture fragments. Normally there is some x-ray evidence of bridging bone formation by

three months. Healing is said to be delayed if there are no signs by then. However, healing can still occur without further intervention. Nonunion is the state when (in the opinion of the treating doctor) healing will not occur without intervention. It is often a difficult decision and may require CT scans to confirm the presence of a gap between the fracture fragments. This gap has scar tissue in it but no bone. The symptoms of a non-union of a thigh bone are pain made worse by bearing weight or stressing the leg. In extreme cases there is detectable movement at the non-union site.

Nonunion is more common with non-operative (traction) treatment of the injury but can occur after surgical fixation especially if there is a large gap between the fragments or an infection. If the fracture was initially treated nonoperatively the first line of treatment would be surgery to hold the fracture immobile. Usually this would be supplemented by bone graft or other material implanted to stimulate bone growth. If the bone has been treated with a locked IM rod the first line of treatment might be to remove the locking screws and allow the weight of the patient to compress the fracture site. This often improves the healing process. Alternatively the rod may be removed and replaced with a larger one, with or without bone grafting. The surgical treatment of non-union is a controversial issue and will vary according to the case. Non-union is usually an intolerable problem and treatment continues until the bone heals.

Infection

An infected fracture occurs when bacteria seed to the fracture site and start to grow in the blood clot near the injury. This happens most commonly with open fractures because of contamination. It also occurs after surgery because the skin barrier is breached. Very rarely bacteria spread in the blood stream to the fracture site and cause an infection in a closed fracture which has not been operated on. When the bacteria invade the bone (osteomyelitis) they are difficult to eliminate. Avoiding infection is the major reason for non-operative treatment. The infection rate following surgery may be as high as 2% in modern hospitals and a good deal higher in developing medical systems. Infection in a fracture is difficult to deal with and may affect the long term outcome. As a result surgeons were very hesitant to operate on fractures. Nowadays the benefit from surgery (straight bones, rapid healing and recovery of function) is considered to outweigh the risks of infection. There have been advances in the prevention of infection and in its treatment. Antibiotics are routinely used during and after most operations on fractures.

An infection in a fracture usually declares itself as increasing pain, swelling and tenderness at the site of surgery. Drainage of pus from the wound makes the diagnosis certain. The treatment is long term antibiotics to supplement the body's defenses and surgery to remove dead and contaminated tissue to give the defense a better chance. This operation is called debridement and may be followed by packing the wound with beads containing antibiotics. It may also be necessary to remove or change the hardware which is keeping the fracture still. Generally speaking, the treatment of infection is successful in suppressing it and allowing the bone to heal. However, the infection may arise again after many years, if it is not completely eliminated.

Venous Thrombo-Embolism (VTE)

After an injury nature activates the clotting system of the body to stop the bleeding. This may have the effect of causing blood to clot in the veins, especially if the circulation is sluggish and the limb is immobile. Clots in the deep veins (Deep Vein Thrombosis, DVT) may cause

symptoms of pain, swelling and purple discoloration. However, quite often the condition does not show symptoms. The most dangerous situation is when the clots in the veins break off and travel in the blood stream to the lungs. This is called Pulmonary Embolism and may cut off the blood supply to the lung with fatal consequences.

VTE is relatively rare in thigh bone fractures treated operatively. It is made less likely by early mobilization of the patient after surgery. However, the nurses and doctors keep a careful watch for signs and symptoms. Treatment of the problem involves using medications that reduce the tendency of the blood to clot. These "blood-thinners" may be continued for months after the complication has been discovered. If it recurs then they may continue for life. More rarely, a filter is placed surgically in the main vein leading up to the heart to prevent any clots from getting to the lungs. Blood-thinners have their own set of associated complications so they are not used as a routine.

Compartment Syndrome

This is not common following a thigh bone fracture. Pressure builds up in the muscle compartments of the thigh resulting in severe, unrelenting pain made worse by active and passive movement. The treatment is to operate to relieve the pressure by decompressing the muscle compartments. If this problem is diagnosed and treated early the outcome is satisfactory.

[LINK: [A Patient's Guide to Fractures](#)]

Stiffness

Thigh bone fractures are accompanied by a great deal of damage to the surrounding muscles. If these muscles scar down to the bone as they heal they will not allow normal movement of the knee. When the treatment consisted of long periods of immobilization in traction or in a [cast](#) this type of stiffness was common. Extensive surgery was undertaken to free up the limb after everything had healed. Where the fracture can be stabilized by surgery, movement of the knee in the recovery period should prevent this complication.

Post Traumatic Arthritis

This is not common following isolated thigh bone fractures as the joints are not directly affected. If there is significant malunion or stiffness there may be a risk of arthritis in the long term.

Associated Injuries

Because it takes a lot of force to break a thigh bone it is not unusual for there to be more than one break in the leg. This may be obvious like a broken shin bone or it may be difficult to distinguish from the shaft fracture, like a [hip fracture](#). Fractures of the knee cap are quite commonly associated, as are fractures and dislocations of the hip socket. Fractures of the bones of the foot may also occur with thigh bone fractures and may be inconspicuous enough to be missed in the initial assessment.

Summary

A fracture of the shaft of the thigh bone is a serious injury with the potential for severe long term problems. It is also commonly associated with other injuries. Modern treatment with Intramedullary Rod fixation fixes the fracture in a good position and allows early mobilization, pain relief and discharge from hospital. Complications from this type of treatment are relatively rare and it is normal to return to full activity. Full recovery can take up to 18 months.
